

One-Year Clinical Results after Epi-LASIK for Myopia

Vikentia J. Katsanevaki, MD, PhD,^{1,2} Maria I. Kalyvianaki, MD,^{1,2} Dimitra S. Kavroulaki, MD,¹
Ioannis G. Pallikaris, MD, PhD^{1,2}

Purpose: To evaluate the clinical results of epi-LASIK for the treatment of low to moderate myopia and myopic astigmatism.

Design: Retrospective, noncomparative, interventional case series.

Participants: Two hundred thirty-four eyes of 138 patients underwent epi-LASIK for the correction of low to moderate myopia. Mean preoperative spherical equivalent ranged from -1.0 to -7.25 diopters (D) (-3.74 ± 1.46 , mean \pm standard deviation [SD]) and baseline logarithm of the minimum angle of resolution (logMAR) best spectacle-corrected visual acuity (BSCVA) from 0.10 to -0.18 (mean \pm SD, 0.00 ± 0.06).

Methods: All enrolled eyes underwent epi-LASIK using the Centurion SES epikeratome (Norwood Abbey EyeCare, Victoria, Australia) and the Allegretto (Wavelight Laser Technologie AG, Erlangen, Germany) laser platform. The enrolled patients were followed up daily until the epithelial healing was complete as well as at the 1-, 3-, 6-, and 12-month postoperative intervals.

Main Outcome Measures: The main parameters assessed were subjective evaluation of postoperative pain, uncorrected visual acuity (UCVA) and BSCVA, manifest refraction, haze grade, and contrast sensitivity of the operated eyes.

Results: The mean epithelial healing time was 4.70 ± 0.87 days (range, 3–7 days), with mean logMAR UCVA on the day of reepithelization of 0.26 ± 0.14 (range, 0.7–0.0). One year after the treatment, the spherical equivalent of the treated eyes ($n = 222$) ranged from -1.25 to $+0.625$ D (mean \pm SD, -0.18 ± 0.6 D), with 80.33% of the eyes within 0.5 D (96.72% within 1 D) of the attempted correction. At the same interval, 86% of the eyes had clear corneas and 14% clinically insignificant (trace) haze, whereas 60% of the eyes had a line gain of 1 or more lines of BSCVA. Mean logMAR contrast sensitivity of the treated eyes at 4 different spatial frequencies was improved or remained unchanged throughout the follow-up period.

Conclusions: One-year visual and refractive results after epi-LASIK suggest that it is a safe and efficient method for the correction of low to moderate myopia and myopic astigmatism. *Ophthalmology* 2007;114:1111–1117 © 2007 by the American Academy of Ophthalmology.

As compared with LASIK, surface ablation procedures are less invasive (in terms of corneal biomechanics), prevent any microkeratome related-complications, and provide the only alternative for laser vision correction for eyes with either thin or neovascularized corneas or deep-set eyes. The idea of Camellin and Cimberle,¹ Camellin,² and others^{3,4} to maintain an epithelial flap that can be replaced on the cornea after photoablation has renewed the interest of refractive surgeons toward surface treatments.

Lee et al⁵ provided the first clinical evidence that patients treated with laser epithelial keratomileusis (LASEK) for low and moderate myopia had lower postoperative pain and haze scores than patients treated with photorefractive keratectomy (PRK). Although the beneficial effect of the retained epithelial sheet has been questioned by other investigators,⁶ an increasing number of authors suggest that the replacement of epithelium onto the ablated cornea may provide advantages over conventional PRK for the correction of myopia.^{1–13}

Epi-LASIK recently was described by Pallikaris et al^{14,15} as an alternative to LASEK for the correction of myopia and myopic astigmatism. Epi-LASIK's fundamental difference from LASEK is that the separation of the epithelial sheet is obtained mechanically without requiring the preparation of the cornea with alcohol or another chemical agent. Mechanical separation not only prevents any potential toxic effect of alcohol^{16–19} on the separated epithelial sheet, but also provides a rather automated surgical procedure with a short learning curve for an experienced refractive surgeon. In the current report, we present the 1-year clinical results after epi-LASIK for the correction of low to moderate myopia and myopic astigmatism.

Originally received: February 1, 2006.

Accepted: August 17, 2006.

Manuscript no. 2006-139.

¹ Institute of Vision & Optics, Heraklion, Greece.

² Department of Ophthalmology, University Hospital of Heraklion, Heraklion, Greece.

Dr Pallikaris is a patent holder of the Centurion SES epikeratome. Norwood Abbey EyeCare supports Dr Katsanevaki's travel expenses in meetings. The remaining authors have no financial interest in any device or instrument reported herein.

Correspondence to Vikentia J. Katsanevaki, MD, PhD, University of Crete, Medical School, P.O. Box 1352, Heraklion, Greece. E-mail: vikatsan@med.uoc.gr.

Patients and Methods

Patient Population

In this retrospective study, 241 eyes of 143 patients underwent epi-LASIK for the correction of myopia and myopic astigmatism. Mean patient age (\pm standard deviation [SD]) was 26.8 ± 6.7 years (range, 18–54). Enrolled patients fulfilled the general criteria for undergoing laser vision correction: stable refraction, no ocular disease, and no previous refractive surgery or systemic disease likely to affect the epithelial healing. Furthermore, enrolled patients had either anatomic limitations to undergoing LASIK surgery (estimated residual stromal thickness under the flap of less than $280 \mu\text{m}$) or expressed a preference to undergo a surface ablation procedure for the correction of their refractive error. Finally, all enrolled patients were local and confirmed that they would be available for follow-up for at least 1 year after the surgery.

The preoperative examination included manifest and cycloplegic refraction, corneal videokeratography (Technomed, C-Scan, Baesweiler, Germany), biomicroscopy, mesopic pupil size measurement (pupillometer, Colvard, Glendora, CA), applanation tonometry, contrast sensitivity testing (CSV-1000, VectorVision, Greenville, OH), and dilated funduscopy. Uncorrected visual acuity (UCVA) and best spectacle-corrected visual acuity (BSCVA) were measured using a back-illuminated logarithm of the minimum angle of resolution (logMAR) chart with a luminance of 160 cd/m^2 .

All the operations were performed by 2 of the authors (VJK, IGP) at the Institute of Vision and Optics, University of Crete, from May 2003 through August 2004. The epithelial separations were performed using the Centurion Epi Edge epikeratome (Norwood Abbey EyeCare, Victoria, Australia) operating with first-generation separators (Separator model no. 007, Norwood Abbey EyeCare). With the exception of fellow eyes of patients who had complicated epithelial separations on the first treated eye, we used 1 separator for treating both eyes of each patient. All the laser treatments were performed using the 200-Hz Allegretto laser platform (Wavelight Technologie AG, Erlangen, Germany) at treatment zones of up to 7 mm according to the patient's mesopic pupil size, as has been previously described.²⁰

In the current series, we used plano Focus Night & Day bandage contact lenses (CIBA Vision Ophthalmics, Embrach, Switzerland). Postoperative medication included diclofenac sodium 0.1% 4 times daily (Denaclor, CIBA Vision Ophthalmics) for 2 days and combined eye drops of tobramycin-dexamethasone 4 times daily (Tobradex, Alcon Laboratories Inc., Fort Worth, TX) until the completion of corneal surface reepithelization.

Patients who reported burning pain of grade 3 or worse (on a predetermined grade scale as described below) received a single dose of oral diclofenac sodium via enteric-coated 25-mg tablets on the operative day, followed by diluted anesthetic eye drops (20% tetracaine in natural tears 4 times daily) prepared in the office. After surface healing was complete, all treated eyes received fluorometholone eye drops 4 times daily (Refresh, Allergan, Irvine, CA) in a tapered dose for 5 weeks. Prescribed artificial tears (Refresh, Allergan) were prescribed to be used at the patient's discretion.

The patients were informed about the investigative character of the procedure and the alternative surgical methods for the correction of their refractive error and signed a consent form according to the Declaration of Helsinki. Institutional review board/ethics committee approval was not required for this study.

Follow-up

Patients were followed up daily by one of the authors (VJK) until the epithelial healing was complete and the therapeutic lens was removed. Examination during the early postoperative period included recording of UCVA and biomicroscopy. Slit-lamp examination allowed for the observation of epithelial healing without requiring the removal of the contact lens, which could dislocate the replaced epithelial flap. Pain scores were evaluated according to a predetermined scale ranging from 0 to 4 as follows: 0, no discomfort or pain; 1, mild discomfort; 2, moderate burning pain; 3, burning pain that required medication; and 4, severe, constant, or sharp pain. The patients received the questionnaire forms after the surgery and were asked to record pain scores every 2 hours for a total of 5 records on the operative day. The questionnaires were collected and evaluated on the first postoperative day visit, including an additional evaluation corresponding to the 24-hour postoperative interval.

After the removal of the bandage contact lens, patients were followed up at 1-, 3-, 6-, and 12-month postoperative intervals. Examination included manifest refraction, biomicroscopy, applanation tonometry videokeratography, and contrast sensitivity testing. Subepithelial haze was graded according to a predetermined scale²¹ as follows: 0, clear cornea; 1, trace haze that could be seen only with broad beam illumination; 2, mild haze visible by slit beam illumination; 3, moderate haze somewhat obscuring iris details; and 4, marked haze obscuring iris details. Data were collected on standardized case report forms and then entered into a central database for analysis. Statistical analysis was performed using SPSS statistical software (version 11.01, SPSS, Inc., Chicago, IL).

Results

The operation was completed uneventfully in 97.1% of the enrolled eyes. Because of complicated epithelial separations, 7 eyes (2.99%) of 5 patients enrolled in the study were operated with alternative surgical procedures. The operative details as well as the refractive and visual results of these complicated eyes are reported separately in the current study.

The mean (\pm SD) preoperative spherical equivalent refraction of the enrolled eyes was -3.74 ± 1.46 diopters (D; range, -1.0 to -7.25 D) with a mean (\pm SD) refractive cylinder of -0.65 ± 0.62 D (range, 0 to -3.00 D). Mean preoperative logMAR BSCVA was -0.00 ± 0.06 (range, 0.10 to -0.18). The mean (\pm SD) preoperative log contrast sensitivities at spatial frequencies of 3, 6, 12, and 18 cycles/degree were 1.61 ± 0.15 , 1.77 ± 0.20 , 1.40 ± 0.22 , and 0.87 ± 0.26 , respectively.

Early Postoperative Period

Epithelial Healing. The mean (\pm SD) time of epithelial healing was 4.7 ± 0.87 days (range, 3–7 days). The epithelial healing was complete by day 5 in the vast majority of the operated eyes ($n = 200$; 85%). Bandage contact lenses were removed on the third day in 34 eyes (10%) and on the seventh day after the operation in 2 eyes (1%).

Pain Scores. The mean pain scores on the operation day remained at less than grade 2 (burning feeling; Fig 1A). However, 16% ($n = 36$) of the patients reported a burning sensation (grade 2) or worse during the first 2 postoperative hours. Seven (3%) of those patients reported burning pain that required medication (grade 3) necessitating prescription of a single dose of oral diclofenac as a sodium enteric-coated 25-mg tablet followed by topical diluted anesthetic drops (20% tetracaine in natural tears) 4 times-

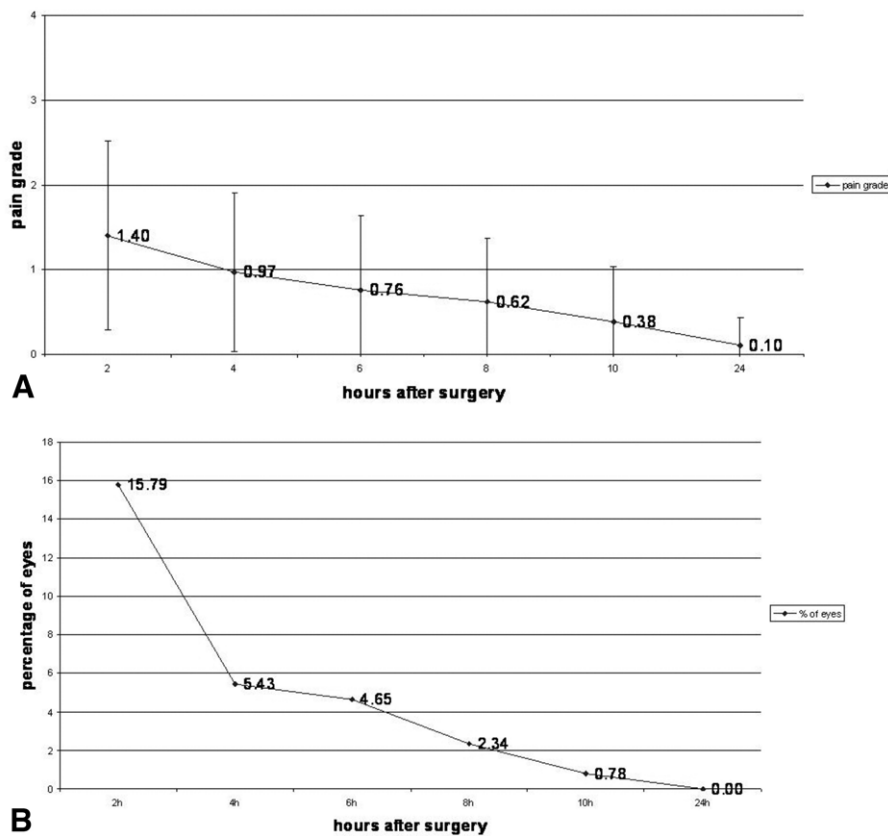


Figure 1. Graphs demonstrating subjective pain scores on the operative day ($n = 234$). **A**, Mean (\pm standard deviation) subjective scores of pain (grades 0–4) during the first 24 hours after epi-LASIK. The mean values showed a tendency to decline with time from surgery and remained below the threshold of moderate burning feeling (grade 2) at all intervals. **B**, Percentage of eyes with subjective pain scores of grade 2 or worse during the first 24 hours after the surgery (also see text).

daily for the next 24 hours (Fig 1B). On day 3, 32 patients (14%) reported mild discomfort as a new symptom, which did not require any medication beyond standard.

Visual Performance. Figure 2A summarizes the mean logMAR UCVA daily records of the operated eyes during the early follow-up period. On the first postoperative day, logMAR UCVA ranged from 0.70 to 0.00 (0.36 ± 0.21 , mean \pm SD). Figure 2B plots the percentage of eyes with vision equal to or better than 20/20 or 20/40 during the early postoperative period.

Late Postoperative Period

Two hundred twenty-two of the 234 patients who were enrolled in the study completed 1 year of follow-up.

Predictability. Figure 3 summarizes the refractive results of the procedure during the follow-up period. One year after the treatment, the mean (\pm SD) spherical equivalent of the operated eyes was -0.18 ± 0.38 , ranging from -1 to 0.625 D (Fig 3A), with 80% ($n = 178$) of the operated eyes within 0.50 D (97% within 1 D; $n = 215$) of the target refraction (Fig 3B).

Efficacy. At the first postoperative month, mean (\pm SD) logMAR UCVA was 0.09 ± 0.10 (range, 0.50 to -0.10), and 1 year after the treatment it was improved to -0.02 ± 0.08 (range, 0.50 to -0.18 ; Fig 4A), with 86% ($n = 190$) of the treated eyes having a UCVA of 20/20 or better (Fig 4B).

Safety. One month after treatment, 55 (25%) eyes lost at least 1 line of BSCVA. Best-corrected vision, similar to UCVA, kept

improving during the follow-up period; 1 year after treatment, there was no eye with loss of any lines of visual acuity, whereas 133 eyes (60%) gained 1 or more lines of BSCVA (Fig 5).

Contrast Sensitivity. Figure 6 summarizes the changes of mean logMAR contrast sensitivity over time. As compared with baseline, the mean contrast sensitivity was found to be increased at all the examined spatial frequencies at the 3-month postoperative visit. One year after the treatment, increase of mean logMAR contrast sensitivity was statistically significant at the spatial frequencies of 12 and 18 cycles/degree.

Haze Scores. Figure 7 summarizes recorded haze scores during the follow-up period. One patient (1%) had moderate bilateral haze at the first month after the procedure, and a second patient (1%) had bilateral moderate haze at the 3-month postoperative interval. Corneal haze in this cohort was transient and improved over time.

One month after the treatment, 12% of the eyes had mild haze. At 6 months after surgery, there was no record of moderate haze and the percentage of eyes with mild corneal haze declined to 4%. One year after the treatment, all the enrolled eyes had either clear corneas or clinically insignificant trace haze.

Complications. The epithelial separation was complicated in 7 eyes (2.99%) of 5 patients. We did not find any statistically significant difference of either the mean attempted spherical equivalent, sphere or cylinder, or the preoperative mean keratometric values between the complicated eyes and the eyes that had un-

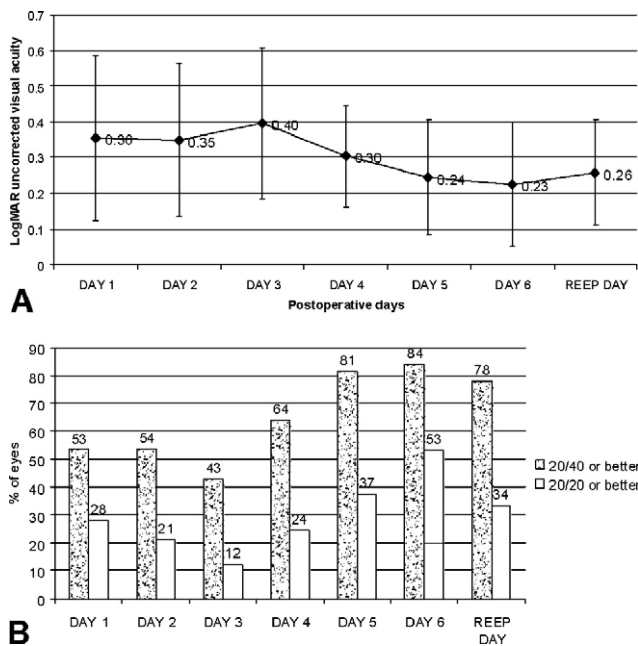


Figure 2. Graphs demonstrating visual rehabilitation after epi-LASIK (n = 234). **A**, Mean (\pm standard deviation) daily records of logarithm of the minimum angle of resolution (logMAR) uncorrected visual acuity during the first postoperative days (until surface healing). **B**, Percentage of eyes with 20/20 and 20/40 visual acuity or better during the early postoperative period. REEP = reepithelization day.

eventful epithelial separations ($P > 0.05$, 2-tailed unpaired Student's *t* test).

In all the complicated cases, the procedure was completed without any suction loss or other particular incidents related to the epikeratome's course during the separation. After the reflection of the epithelial sheet, the surgeon noted that the cleavage plane of the epithelial separation was uneven, including a strip of corneal stroma attached to the epithelial sheet. Because of their minimal size (less than 4 mm in their longest dimension), the thickness measurement of those stromal strips was not possible during surgery.

All complicated patients initially were scheduled for bilateral epi-LASIK. Routinely, we use the same separator for the 2 eyes of the same patient, treating the right eye first. In the cases of stromal incursion on the right eye, we used a new separator for the fellow eye. Despite the change of the separator, the stromal crease was bilateral in 2 patients. In the 3 patients left, the inadvertent stromal incursion occurred in the left eye.

In 5 eyes of 3 patients the stromal crease was limited to the upper periphery of the separated sheet and did not implicate the treatment zone. In those eyes, the operation was completed at the same session, reversing to PRK with additional application of 0.02% mitomycin C for 12 seconds after the completion of the ablation.

In 2 eyes in which the inadvertent stromal incursion implicated the treatment zone, the separated tissue was replaced carefully onto the corneal surface and the operation was postponed. The eyes were monitored daily and received standard topical medication until the completion of surface healing. The refractive stabilization of these 2 eyes was followed up with manifest refraction and consecutive corneal topographies at 1-month intervals after the incident. After stabilization, the eyes were treated with LASIK to avoid the risk of stromal strip dislocation during retreatment. The

LASIK procedure in those 2 eyes was performed after 2 and 3 months, respectively, without any further complications.

The follow-up of the complicated eyes ranged from 11 to 15 months. At the last follow-up visit, all eyes were within 0.5 D of attempted correction without any line loss of BSCVA. The eyes had regular topographic patterns, and the UCVA ranged from 20/25 (2 eyes) to 20/16 (1 eye).

Discussion

Epi-LASIK is an alternative surface ablation procedure for the refractive correction of ametropias. Based on the encouraging clinical¹⁻¹³ and laboratory²² reports of LASEK, epi-LASIK was introduced to provide an advantageous way for the separation of the epithelial sheet.¹⁵ The mechanically separated epithelium, which has been shown to remain intact morphologically at least for the first 24 hours after its replacement,²³ is expected to act as a mechanical barrier between the tear film and the ablated stroma, thus regulating the corneal wound healing. Although the migratory phase of epithelial healing is not eliminated with this method, the epithelial sheet's replacement may have the potential to reduce the risk of haze by disturbing the time relations between epithelial migration and keratocyte activation, after the photorefractive procedure.²⁴

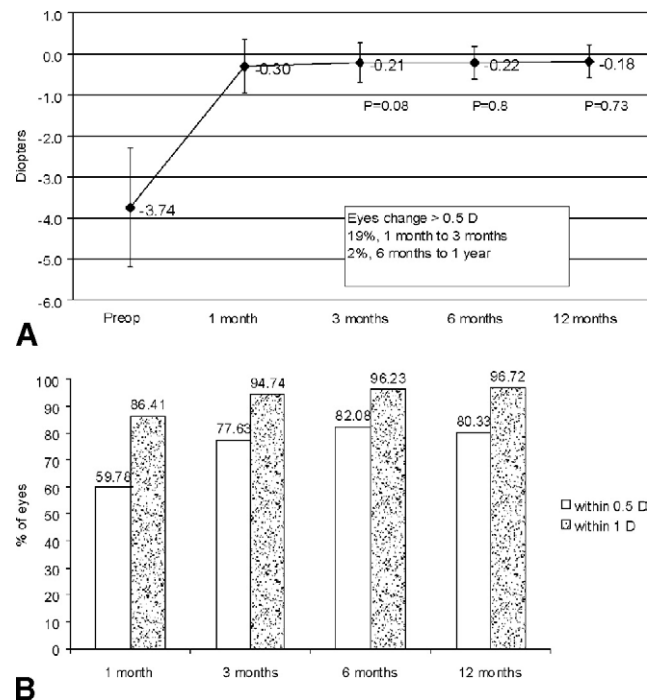


Figure 3. Graphs demonstrating refractive results after myopic epi-LASIK (n = 222). **A**, Mean (\pm standard deviation) spherical equivalent during the follow-up. *P* values represent statistical significance of changes between intervals (Student's *t* test). The refractive result was stabilized at the third month after the surgery. The change of mean spherical equivalent was marginally significant between the first- and third-month postoperative interval. Preop = preoperative. **B**, Percentage of eyes with postoperative spherical equivalent within 0.5 and 1 diopter (D) after myopic epi-LASIK during the follow-up period.

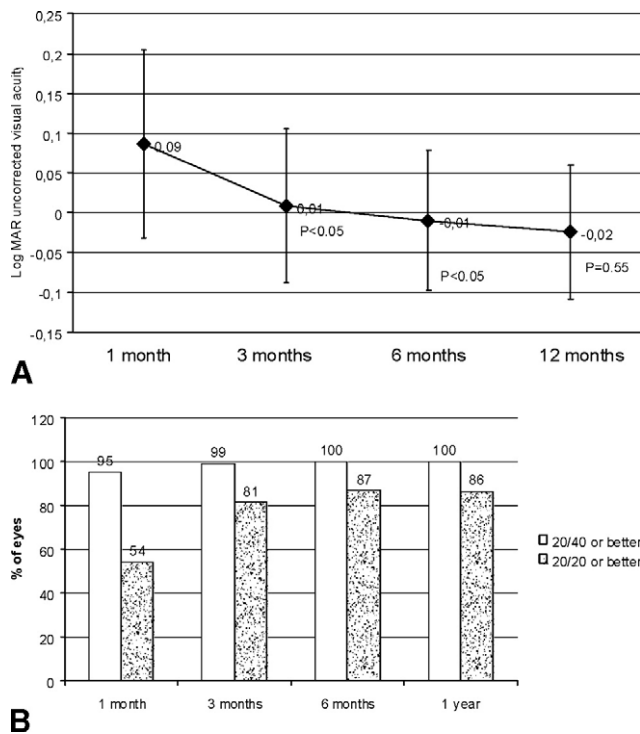


Figure 4. Graphs demonstrating uncorrected visual acuity after myopic epi-LASIK (n = 222). **A**, Mean (\pm standard deviation) logarithm of the minimum angle of resolution (logMAR) uncorrected visual acuity during the follow-up period. *P* values represent statistical significance of changes between intervals (Student's *t* test). We recorded a statistically significant improvement of the treated eyes up to 6 months after surgery. **B**, Percentage of eyes with 20/20 and 20/40 or better during the follow-up period.

Our results provide clinical evidence that epi-LASIK is an efficient method for the correction of myopia up to -7.25 D. One year after the treatment, the operated eyes in our cohort had either clear corneas or clinically insignificant haze, with excellent visual performance and unaffected or even improved (at higher spatial frequencies) contrast sensitivity. Furthermore, a significant percentage of eyes gained 1 or more lines of visual acuity at 1 year. These results correlate well with reports for matching attempted

myopic corrections using alternative surface ablation procedures.¹⁰⁻¹³

The complications of mechanical epithelial separation that were recorded in almost 3% of the treated eyes were related to inadvertent stromal incursion of the separator. Although this complication potentially can influence visual acuity of the operated eye, it did not prove significant for the visual performance in the complicated cases reported herein.

The principle of mechanical epithelium separation is based on the specific mechanical properties of Bowman's layer so that the epikeratome's separator moves forward following the pathway of least local resistance. The inadvertent stromal dissection during its forward movement could be attributed to separator defects (being in part sharper than intended) or to altered local mechanical properties of the epithelium-stroma complex of the complicated eyes. Examination of these particular separators under the surgical microscope did not show any evident deformities. We therefore assume that it is more likely that this complication was the result of anatomic variations in the specific eyes rather than of separator deformities. This assumption is also supported by the fact that the stromal incursion occurred in both eyes of 2 patients despite the separator change.

All the eyes enrolled in the current series were treated with first-generation separators of the Centurion SES epikeratome, operating using settings specified by the unit. Since then, the manufacturer redesigned the angle of the separator to be more blunt and adjusted the recommendations for other parameters, raising the oscillation rate from 10 800 to 12 000 rpm, lowering the speed of head advancement from 4 to 2 mm/minute, and raising the vacuum pressure from 630 to 640 mmHg. These changes eliminated the incidence of stromal incursions in our practice but resulted in free sheet separations in almost 30% of the cases (unpublished data). Free capping is not considered a significant complication; in the vast majority of patients, free cap replacement is possible. New separator modifications are now under investigation that aim to achieve ideal epithelial separations in all eyes.

As also shown in our preliminary report on 3-month clinical results of 44 eyes, epi-LASIK²⁰ is not a totally pain-free procedure. The results of the current series confirmed that a small percentage of patients experience pain,

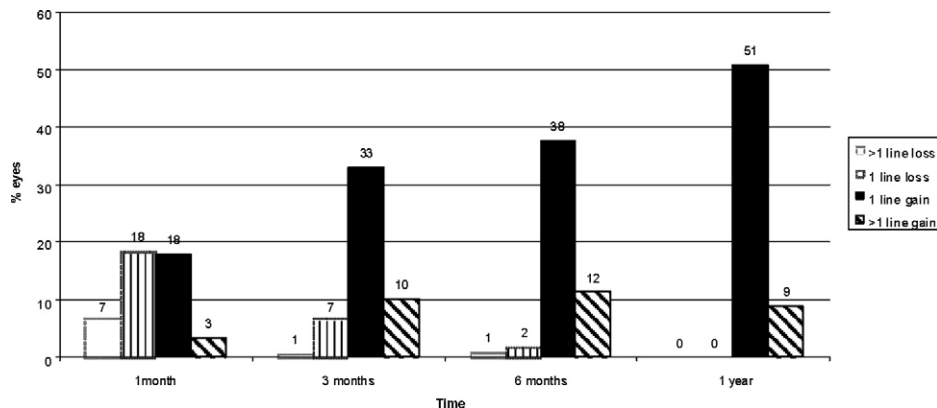


Figure 5. Bar graph demonstrating best-corrected visual acuity Snellen line gain and loss during the follow-up period after myopic epi-LASIK (n = 222). As shown in the chart, there is an improvement of line gain with concomitant improvement of line loss during the follow-up.

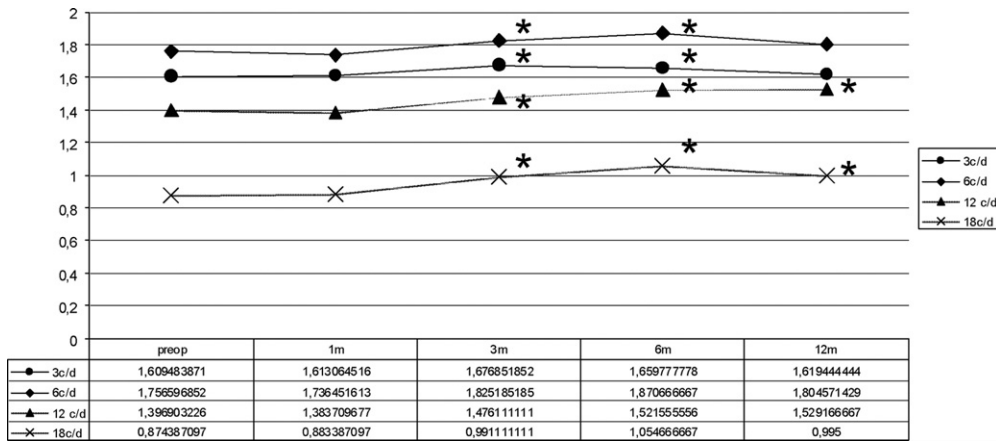


Figure 6. Graph demonstrating the mean logarithm of the minimum angle of resolution contrast sensitivity measures in 4 different spatial frequencies during the follow-up period (n = 222). Asterisks mark statistically significant changes at each interval as compared with the preoperative (preop) values for every spatial frequency (statistical significance at the level of $P < 0.05$, Student's *t* test). c/d = cycles/degree; m = months.

especially during the first few hours after surgery. Our results showed that this percentage declined with time from surgery, with patients reporting discomfort only after the first 24 postoperative hours. Using a 4-point scale similar to ours, Aufrata and Rehurek¹² compared the levels of postoperative pain between PRK and LASEK in a prospective randomized study. As compared with PRK, LASEK-treated eyes had lower levels of pain. Similar to our results, after the first postoperative day, pain after LASEK remained at the level of discomfort. However, the beneficial effect of the replaced epithelial flap has been questioned by a number of investigators reporting equal²⁵⁻²⁷ or even worse^{6,28} levels of pain after LASEK as compared with conventional PRK. We could assume that the variety of alcohol concentrations as well as the different alcohol application times among studies may result in various effects of alcohol on the epithelial sheet itself and, therefore, variable postoperative pain results. Future studies comparing postoperative pain levels between (alcohol-free) epi-LASIK treatments and conventional PRK will give answers regarding the effect of the replaced epithelial sheet on the control of postoperative pain after surface ablation.

The slow visual rehabilitation of the eyes treated with epi-LASIK also remains an issue; the mean logMAR UCVA on the reepithelization day was 0.23, with only 34% of the eyes having unaided vision of 20/20 or better. Fur-

thermore, at the first month after the surgery, 25% of eyes had a ≥ 1 -line loss of BSCVA. We assume that this finding is related to surface changes, because visual performance improved substantially during the follow-up period (Fig 5).

In addition to specific indications that necessitate surface treatment instead of LASIK, our experience showed that a percentage of well-informed patients are willing to undergo epi-LASIK despite the slower visual recovery as compared with LASIK. Currently, epi-LASIK comprises almost 30% of our refractive practice.

Recent peer-reviewed studies²⁹⁻³¹ comparing surface treatments and LASIK fail to show any significant benefit of LASIK in the long term. The 1-year results of the current series provide evidence that at 12 months, epi-LASIK offers excellent refractive and visual outcome with clinically insignificant haze; however, the occurrence of inadvertent stromal incursions during epithelial separations remains an important issue to be addressed.

In the current series, the small percentage of eyes with stromal incursion during separation was managed successfully without any adverse visual effect. However, the small number of complicated cases in the current report does not allow us to conclude that this is not a potentially sight-threatening complication. Apprehension of the mechanism and identification of the risk factors for inadvertent stromal incursion during mechanical epithelial separation likely will help to eliminate this significant complication in the future. Much like the evolution of LASIK, the future predominance of epi-LASIK over other photorefractive procedures likely will depend on the development of safe epikeratome devices.

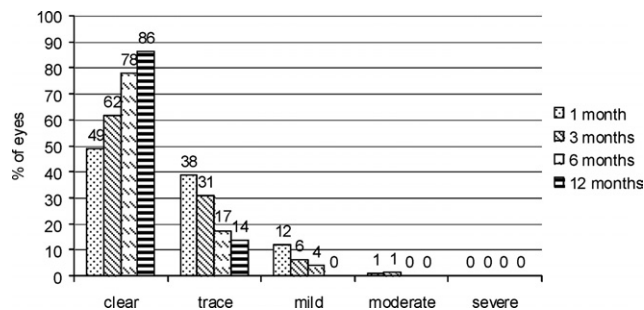


Figure 7. Bar graph demonstrating records of corneal haze during the follow-up period after myopic epi-LASIK (n = 222).

References

1. Camellin M, Cimberle M. LASEK technique promising after 1 year of experience. *Ocular Surg News* 2000;18:14-7.
2. Camellin M. Laser epithelial keratomileusis for myopia. *J Refract Surg* 2003;19:666-70.
3. Azar DT, Ang RT, Lee JB, et al. Laser subepithelial keratomileusis: electron microscopy and visual outcomes of

- photorefractive keratectomy. *Curr Opin Ophthalmol* 2001; 12:323–8.
4. Shah S, Sebai Sarhan AR, Doyle SJ, et al. The epithelial flap for photorefractive keratectomy. *Br J Ophthalmol* 2001;85: 393–6.
 5. Lee JB, Seong GJ, Lee JH, et al. Comparison of laser epithelial keratomileusis and photorefractive keratectomy for low to moderate myopia. *J Cataract Refract Surg* 2001;27:565–70.
 6. Litwak S, Zadok D, Garcia-de Quevedo V, et al. Laser-assisted subepithelial keratectomy versus photorefractive keratectomy for the correction of myopia: a prospective comparative study. *J Cataract Refract Surg* 2002;28:1330–3.
 7. Shahinian L. Laser-assisted subepithelial keratectomy for low to high myopia and astigmatism. *J Cataract Refract Surg* 2002;28:1334–42.
 8. Rouweyha RM, Chuang AZ, Mitra S, et al. Laser epithelial keratomileusis for myopia with the autonomous Laser. *J Refract Surg* 2002;18:217–24.
 9. Kornilovsky IM. Clinical results after subepithelial photorefractive keratectomy (LASEK). *J Refract Surg* 2001;17(suppl): S222–3.
 10. Claringbold TV II. Laser-assisted subepithelial keratectomy for the correction of myopia. *J Cataract Refract Surg* 2002; 28:18–22.
 11. Anderson NJ, Beran RF, Schneider TL. Epi-LASEK for the correction of myopia and myopic astigmatism. *J Cataract Refract Surg* 2002;28:1343–7.
 12. Atrata R, Rehurek J. Laser-assisted subepithelial keratectomy for myopia: two-year follow-up. *J Cataract Refract Surg* 2003;29:661–8.
 13. Chalita MR, Tekwani NH, Krueger RR. Laser epithelial keratomileusis: outcome of initial cases performed by an experienced surgeon. *J Refract Surg* 2003;19:412–5.
 14. Pallikaris IG, Katsanevaki VJ, Kalyvianaki MI, Naoumidi II. Advances in subepithelial excimer refractive surgery techniques: epi-LASIK. *Curr Opin Ophthalmol* 2003;14: 207–12.
 15. Pallikaris IG, Naoumidi II, Kalyvianaki MI, Katsanevaki VJ. Epi-LASIK: comparative histological evaluation of mechanical and alcohol-assisted epithelial separation. *J Cataract Refract Surg* 2003;29:1496–501.
 16. Gabler B, Winkler von Mohrenfelds C, Dreiss AK, et al. Vitality of epithelial cells after alcohol exposure during laser-assisted subepithelial keratectomy flap preparation. *J Cataract Refract Surg* 2002;28:1841–6.
 17. Kim SY, Sah WJ, Lim YW, Hahn TW. Twenty percent alcohol toxicity on rabbit corneal epithelial cells: electron microscopic study. *Cornea* 2002;21:388–92.
 18. Chen CC, Chang JH, Lee JB, et al. Human corneal epithelial cell viability and morphology after dilute alcohol exposure. *Invest Ophthalmol Vis Sci* 2002;43:2593–602.
 19. Stramer BM, Zieske JD, Jung JC, et al. Molecular mechanisms controlling the fibrotic repair phenotype in cornea: implications for surgical outcomes. *Invest Ophthalmol Vis Sci* 2003; 44:4237–46.
 20. Pallikaris IG, Kalyvianaki MI, Katsanevaki VJ, Ginis HS. Epi-LASIK: preliminary clinical results of an alternative surface ablation procedure. *J Cataract Refract Surg* 2005;31:879–85.
 21. Seiler T, Wollensak J. Myopic photorefractive keratectomy with the excimer laser: one-year follow-up. *Ophthalmology* 1991;98:1156–63.
 22. Esquenazi S, He J, Bazan NG, Bazan HE. Comparison of corneal wound-healing response in photorefractive keratectomy and laser-assisted subepithelial keratectomy. *J Cataract Refract Surg* 2005;31:1632–9.
 23. Katsanevaki VJ, Naoumidi II, Kalyvianaki MI, Pallikaris IG. Epi-LASIK: histological findings of separated epithelial sheets 24 hours after treatment. *J Refract Surg* 2006;22: 151–4.
 24. Rajan MS, Watters W, Patmore A, Marshall J. In vitro human corneal model to investigate stromal epithelial interactions following refractive surgery. *J Cataract Refract Surg* 2005;31: 1789–801.
 25. Hashemi H, Fotouhi A, Foudazi H, et al. Prospective, randomized, paired comparison of laser epithelial keratomileusis and photorefractive keratectomy for myopia less than –6.50 diopters. *J Refract Surg* 2004;20:217–22.
 26. Pirouzian A, Thornton JA, Ngo S. A randomized prospective clinical trial comparing laser subepithelial keratomileusis and photorefractive keratectomy. *Arch Ophthalmol* 2004;122: 11–6.
 27. Lee HK, Lee KS, Kim JK, et al. Epithelial healing and clinical outcomes in excimer laser photorefractive surgery following three epithelial removal techniques: mechanical, alcohol and excimer laser. *Am J Ophthalmol* 2005;139:56–63.
 28. Blake CR, Cervantes-Castaneda RA, Macias-Rodriguez Y, et al. Comparison of postoperative pain in patients following photorefractive keratectomy versus advanced surface ablation. *J Cataract Refract Surg* 2005;31:1314–9.
 29. el Danasouri MA, el Maghraby A, Klyce SD, Mehrez K. Comparison of photorefractive keratectomy with excimer laser in situ keratomileusis in correcting low myopia (from –2.00 to –5.50 diopters): a randomized study. *Ophthalmology* 1999;106:411–20, discussion 420–1.
 30. El-Maghraby A, Salah T, Waring GO III, et al. Randomized bilateral comparison of excimer laser in situ keratomileusis and photorefractive keratectomy for 2.50 to 8.00 diopters of myopia. *Ophthalmology* 1999;106:447–57.
 31. Wang Z, Chen J, Yang B. Comparison of laser in situ keratomileusis and photorefractive keratectomy to correct myopia from –1.25 to –6.00 diopters. *J Refract Surg* 1997;13: 528–34.